



# OCT-Angiography Clinical Cases

---

NIDEK RS-3000 Advance  
AngioScan

Daniela Bacherini  
Andrea Sodi  
Stanislao Rizzo

# C CONTENTS

	Page
Authors	3
Introduction	4
Case 1 Neovascular Age-related Macular Degeneration (AMD) - Type I Choroidal Neovascularization (CNV)	6
Case 2 Neovascular Age-related Macular Degeneration (AMD) - Type II Choroidal Neovascularization (CNV)	7
Case 3 Retinal Angiomatous Proliferation (RAP) - Type III Choroidal Neovascularization (CNV)	8
Case 4 Neovascular Age-related Macular Degeneration (AMD) - CNV mixed type: Type I + Type II	9
Case 5 Neovascular Age-related Macular Degeneration (AMD) - Follow Up after Anti-VEGF Treatment	10
Case 6 Atrophic Age-related Macular Degeneration (AMD)	11
Case 7 Myopic Choroidal Neovascularization (CNV)	12
Case 8 Angioid Streaks associated with Choroidal Neovascularization (CNV)	13
Case 9 Advanced Stage Retinitis Pigmentosa (RP)	14
Case 10 Stargardt (STGD) Disease	15
Case 11 X-Linked Retinoschisis	16
Case 12 Choroidal Osteoma complicated by Choroidal Neovascularization (CNV)	17
Case 13 Branch Retinal Vein Occlusion (BRVO)	18
Case 14 Proliferative Diabetic Retinopathy (DR)	19



## AUTHORS

Daniela Bacherini  
Andrea Sodi  
Stanislao Rizzo

Department of Surgery and Translational Medicine  
Ophthalmology, Careggi University Hospital  
University of Florence, Italy

**Dr. Daniela Bacherini, MD**, is completing her Research Doctorate at the Department of Ophthalmology, Careggi University Hospital, University of Florence, Italy. Her clinical and research activities are focused on medical retina with a special interest in retinal imaging, uveitis and retinal dystrophies.

**Dr. Andrea Sodi, MD**, is from the Department of Ophthalmology, Careggi University Hospital, Florence, Italy. His clinical and research activities are focused on medical retina with a special interest in retinal vascular disorders and retinal dystrophies.

**Prof. Stanislao Rizzo, MD**, is the chairman of Department of Ophthalmology, Careggi University Hospital, University of Florence, Italy. He is a vitreoretinal surgeon and his clinical and research activities are mainly focused on retinal diseases and vitreoretinal surgery.

# INTRODUCTION

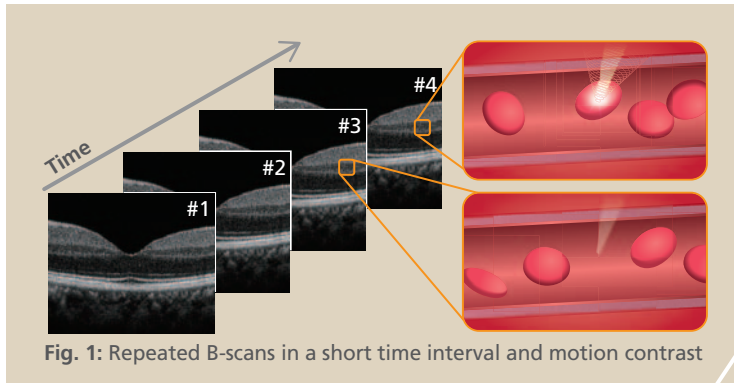


Fig. 1: Repeated B-scans in a short time interval and motion contrast

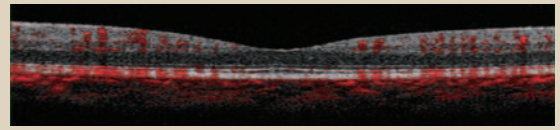


Fig. 2: Overlay between structural B-scan and blood flow signal

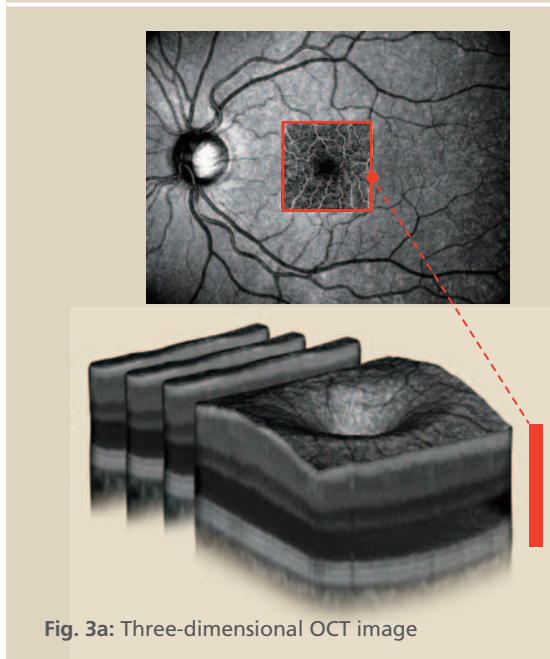


Fig. 3a: Three-dimensional OCT image

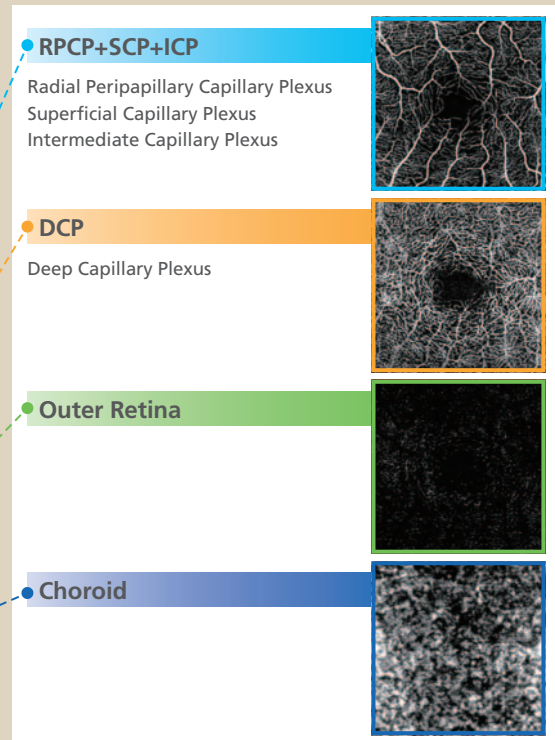


Fig. 3b: En face OCT-A images by different slabs

## ■ Basic Principle of OCT-Angiography

OCT-Angiography (OCT-A) is a non-invasive imaging technique of the retinal and choroidal vasculature and microvasculature. OCT-A uses the principle of “motion contrast” for the detection of blood flow. To generate the images, multiple cross-sectional scans (B-scans) are acquired at the same retinal location over a short time interval. Motion (moving structure such as blood flow) will cause slight differences between these repeated scans. However, if there is no motion contrast, the repeated scans will produce almost the same signal (Fig. 1). On the B-scan image above, the signal generated by blood flow is represented in red (Fig. 2). The volumetric 3D dataset from the whole OCT-A scan can be rendered to reconstruct En face OCT-A images representing the vasculature at different depths within the retina and choroid (Fig. 3a).

## ■ Features of OCT-Angiography

OCT-A does not require an injection of contrast dye, hence it can be performed in patients who require regular follow up without risk of adverse effects of repeated used of dye. Another feature is the ability to perform a layer-by-layer analysis of the vasculature with a 3-dimensional (3D) approach; the entire retina, RPCP+SCP+ICP, DCP, Outer Retina and Choroid (Fig. 3b). OCT-A can provide information of the exact location and extent of choroidal neovascularization (CNV) or non-perfusion area (NPA) for diagnosing AMD or DR. These features are some of the advantages of OCT-A over fluorescein angiography (FA) or indocyanine green angiography (ICG). However, image interpretation of OCT-A differs from FA/ICG because the imaging principles differ. Leakage, pooling or staining regions are normally not detected by OCT-A as they generally do not present enough “motion” to be imaged.

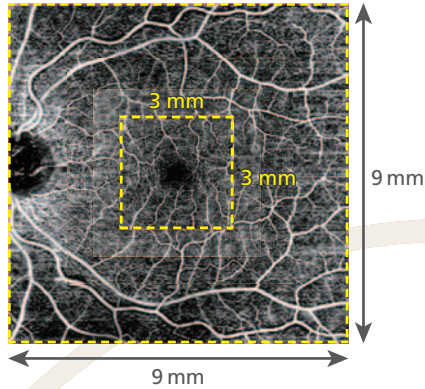
## ■ CODAA (Complex OCT signal Difference Analysis Angiography)

NIDEK’s proprietary motion contrast algorithm “CODAA” detects blood flow by calculating both phase and amplitude variation of the OCT signal over time. The CODAA approach ensures higher sensitivity generating greater image details including microcirculation such as capillary rings.

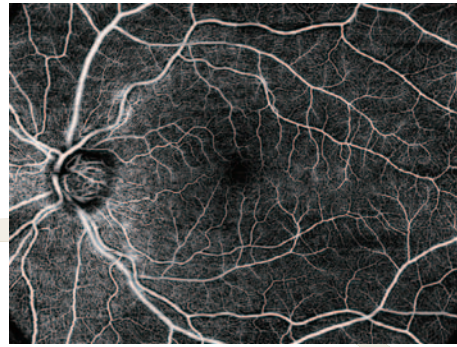## Wide Field OCT-Angiography

For assessment of the retinal periphery

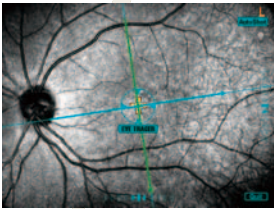
One Map Scan



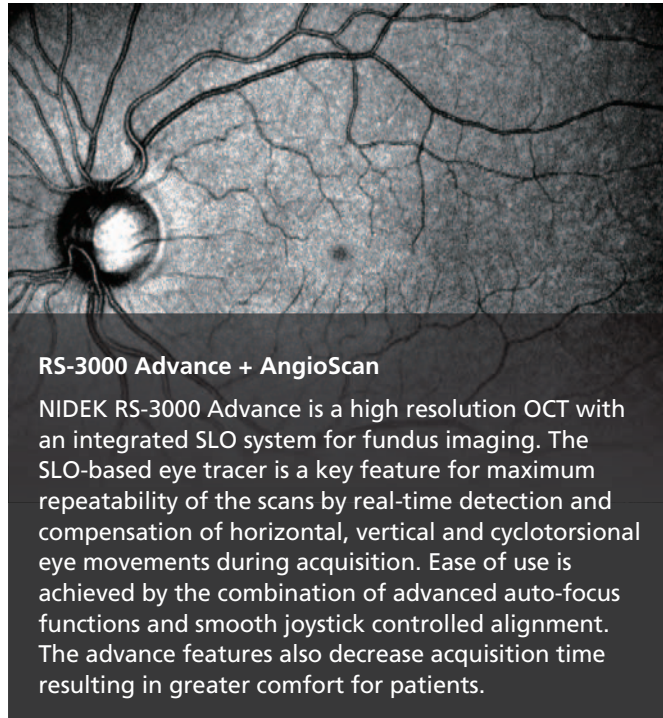
Auto Panorama Image



## Eye Tracer



Real time compensation for eye movements, resulting in more accurate scans, ensuring higher image quality and maximum reproducibility

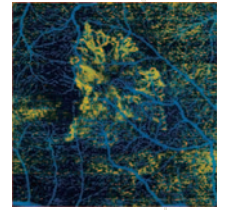


## RS-3000 Advance + AngioScan

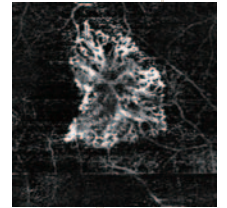
NIDEK RS-3000 Advance is a high resolution OCT with an integrated SLO system for fundus imaging. The SLO-based eye tracer is a key feature for maximum repeatability of the scans by real-time detection and compensation of horizontal, vertical and cyclotorsional eye movements during acquisition. Ease of use is achieved by the combination of advanced auto-focus functions and smooth joystick controlled alignment. The advance features also decrease acquisition time resulting in greater comfort for patients.

## CNV Analysis

For easy visualization and detection of CNV



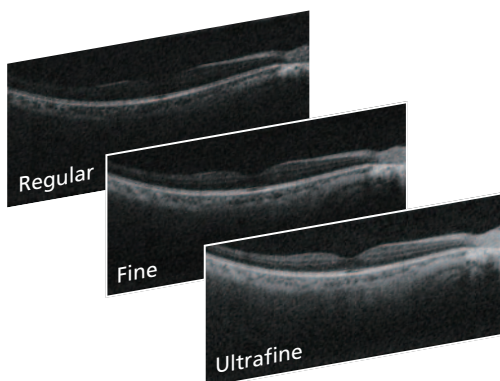
CNV Flow



Projection Artifact Removal

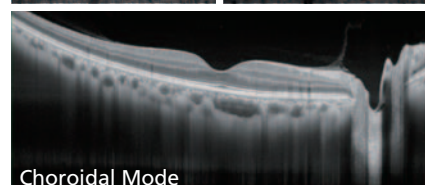
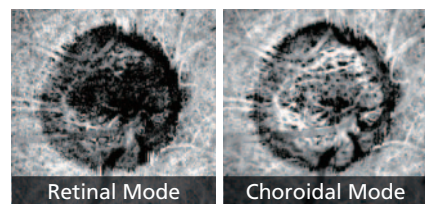
## Selectable OCT Sensitivity

Retinal pathologies in a cataractous eye can be imaged by increasing the OCT sensitivity



## Choroidal Visualization

Allows to evaluate the choroid and visualization of deeper optic nerve head



# Case 1

## Neovascular Age-related Macular Degeneration (AMD) - Type I Choroidal Neovascularization (CNV)

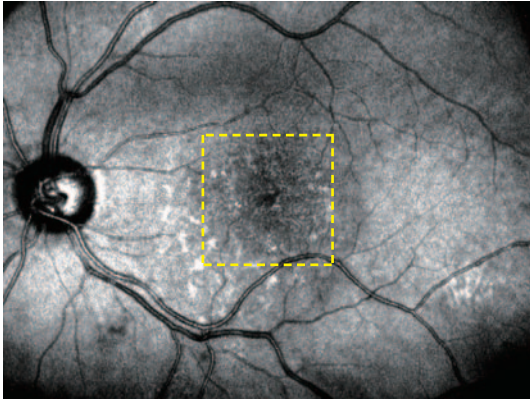


Fig. 1a: SLO

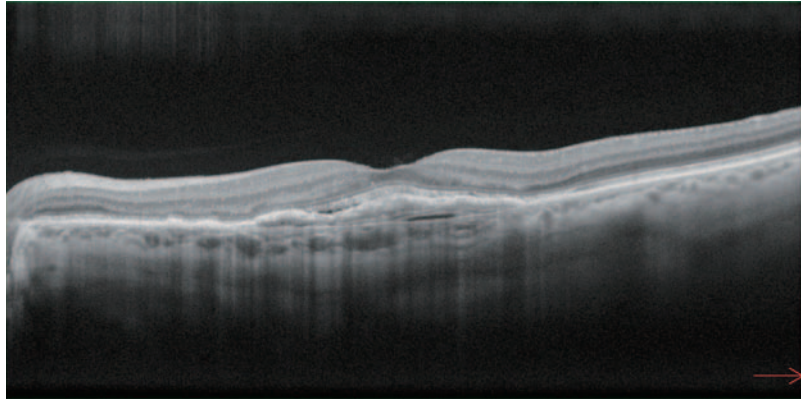


Fig. 1b: OCT B-scan

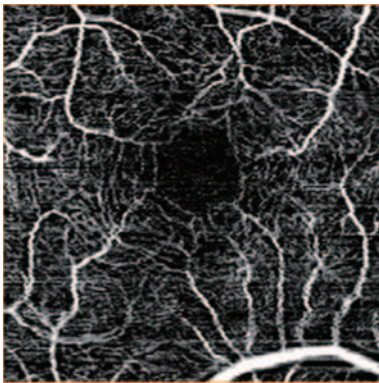


Fig. 2a: OCT-Angiography (SCP)

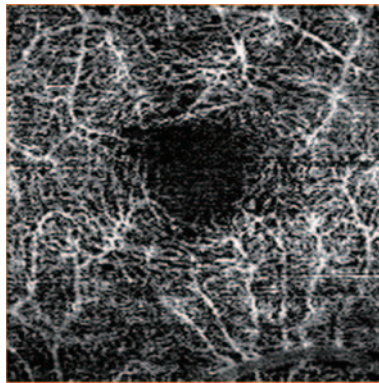


Fig. 2b: OCT-Angiography (DCP)

**Fig. 1a:** The Scanning Laser Ophthalmoscope (SLO) fundus image shows some areas of increased reflectivity with a central hyporeflective area.

**Fig. 1b:** The structural OCT B-scan shows a retinal pigment epithelium (RPE) elevation associated with significant thickening of the ellipsoid zone and subtle subretinal fluid.



Fig. 2c: OCT-Angiography (Outer Retina)

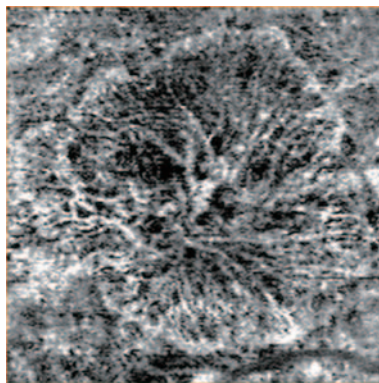


Fig. 2d: OCT-Angiography (Choroid)

### ■ OCT-Angiography: AngioScan Images

**Fig. 2a:** Normal superficial capillary plexus (SCP)

**Fig. 2b:** Normal deep capillary plexus (DCP)

**Fig. 2c:** No signs of abnormal vascularization in the outer retina.

**Fig. 2d:** A large wheel-shaped vascular network is present at the choroidal level. A large central trunk is visible with branches radiating in all directions.

The Type I CNV with new vessels located beneath the RPE has been previously referred to as occult CNV.

# Case 2

## Neovascular Age-related Macular Degeneration (AMD) - Type II Choroidal Neovascularization (CNV)

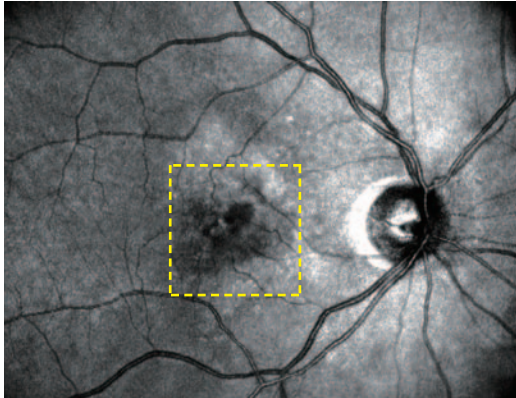


Fig. 1a: SLO

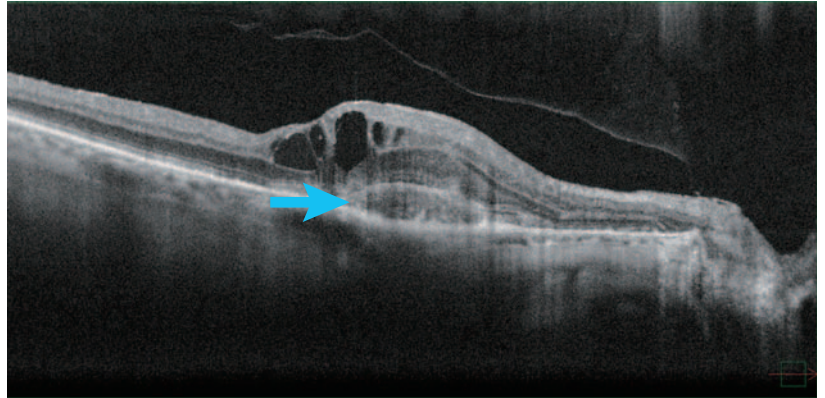


Fig. 1b: OCT B-scan

**Fig. 1a:** SLO fundus image of a hyporeflective halo corresponding to intraretinal fluid in the macular region.

**Fig. 1b:** The structural OCT B-scan shows intraretinal cystoid spaces. A subfoveal hyperreflective thickening is present in the outer retina above the RPE (blue arrow).




Fig. 2a: OCT-Angiography (SCP)




Fig. 2b: OCT-Angiography (DCP)

### ■ OCT-Angiography: AngioScan Images

**Fig. 2a:** Normal superficial capillary plexus (SCP)

**Fig. 2b:** Deep capillary plexus (DCP) with some darker areas of no flow corresponding to multiple cysts (blue arrows).

**Fig. 2c:** A large coral-shaped CNV with multiple branches in the outer retina.

**Fig. 2d:** The choroidal slab shows the origin of the CNV surrounded by a dark halo.

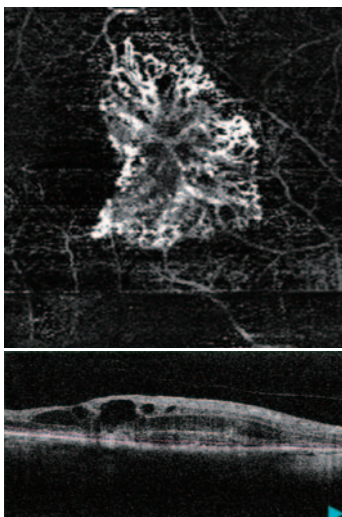


Fig. 2c: OCT-Angiography (Outer Retina)

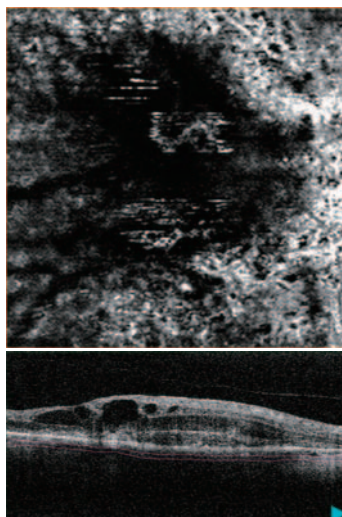


Fig. 2d: OCT-Angiography (Choroid)

The Type II CNV with pre-epithelial new vessels growing into the subretinal space corresponds to classic CNV.

# Case 3

## Retinal Angiomatous Proliferation (RAP) - Type III Choroidal Neovascularization (CNV)

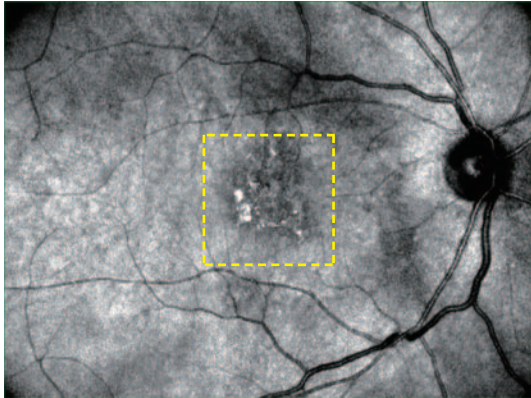


Fig. 1a: SLO

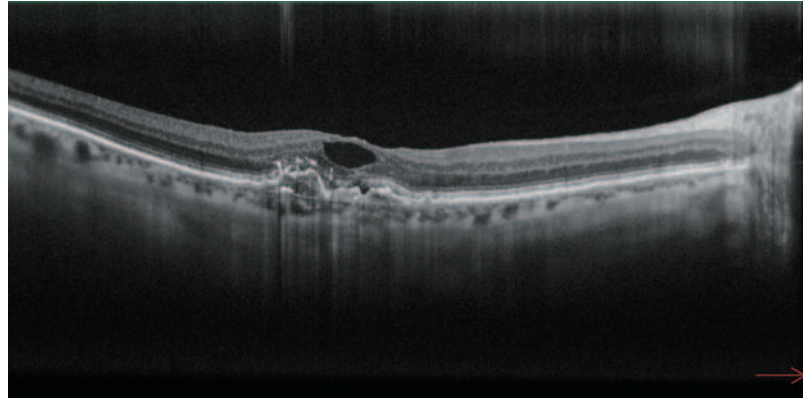


Fig. 1b: OCT B-scan

**Fig. 1a:** The SLO fundus image shows a speckled focal increase of reflectivity in the macular area.

**Fig. 1b:** The structural OCT B-scan shows outer retina disruption and an elevation of the underlying RPE associated to subtle subretinal fluid and an intraretinal cyst.

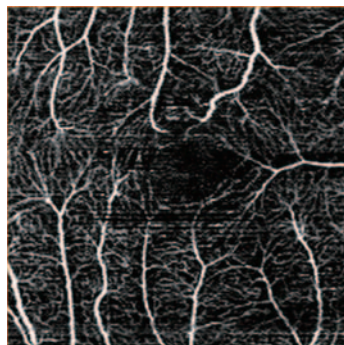


Fig. 2a: OCT-Angiography (SCP)

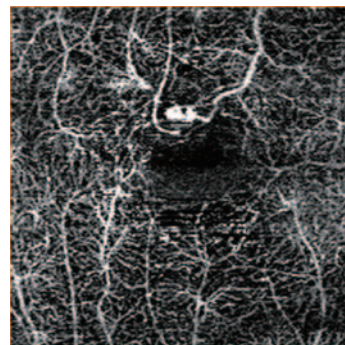


Fig. 2b: OCT-Angiography (DCP)




Fig. 2c: OCT-Angiography  
(Outer Retina)

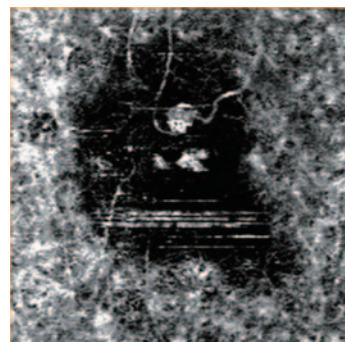


Fig. 2d: OCT-Angiography  
(Choroid)

### ■ OCT-Angiography: AngioScan Images

**Fig. 2a:** Normal superficial capillary plexus (SCP)

**Fig. 2b:** The DCP image shows a small high-flow round lesion that seems to extend downwards into the outer retina (retinal-retinal anastomosis, **Fig. 2c**) and into the choriocapillaris (**Fig. 2d**) where a corresponding small glomerular lesion within a large dark halo is present.

# Case 4

## Neovascular Age-related Macular Degeneration (AMD) - CNV mixed type: Type I + Type II

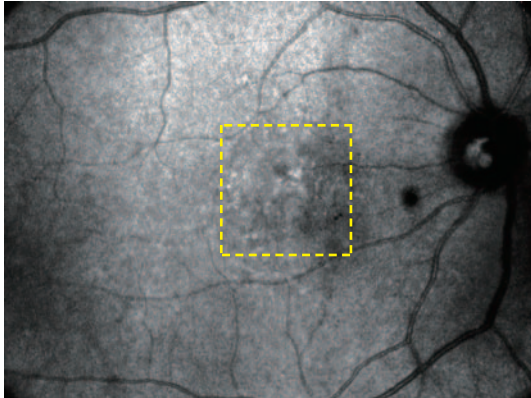


Fig. 1a: SLO

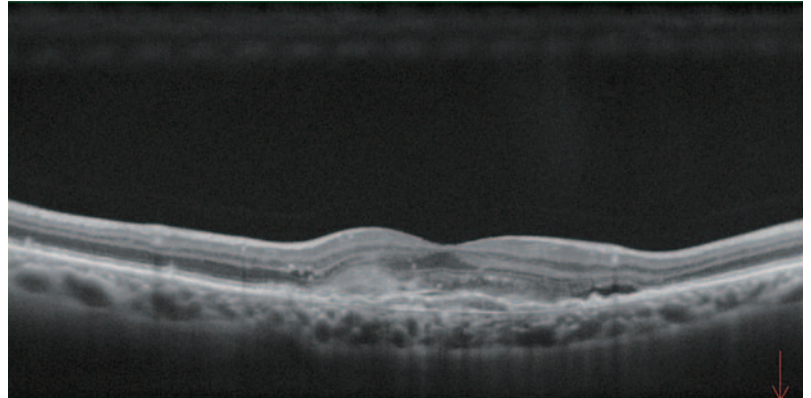


Fig. 1b: OCT B-scan

**Fig. 1a:** The SLO fundus picture shows a combination of hypo- and hyper-reflective alterations in the macular area.

**Fig. 1b:** The structural OCT B-scan shows thickening of neurosensory retina with subretinal fluid. An irregular elevation of RPE extends under the macula associated with disorganization of the outer retinal layers and a subretinal hyperreflective thickening.



Fig. 2a: OCT-Angiography (Outer Retina)

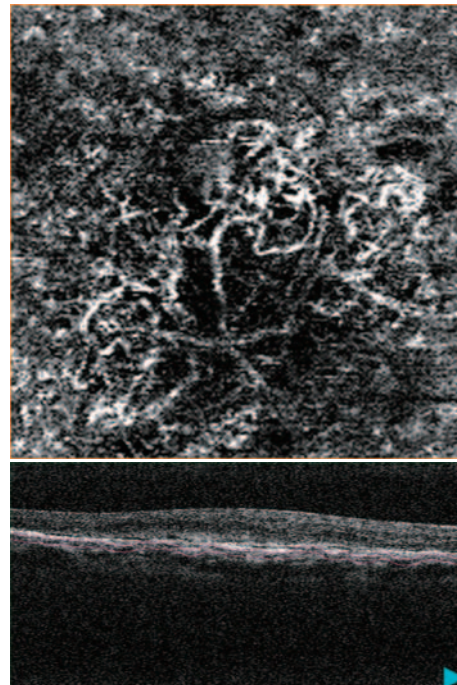


Fig. 2b: OCT-Angiography (Choroid)

### ■ OCT-Angiography: AngioScan Images

**Fig. 2a:** An abnormal flow signal is present in the outer retina, representing the pre-epithelial (Type II) neovascular network.

**Fig. 2b:** In the choroidal slab, OCT-A reveals an additional sub-epithelial (Type I) network with radiating vessels branching from the center to the periphery and rare vascular loops in the periphery of the lesion.

# Case 5

## Neovascular Age-related Macular Degeneration (AMD) - Follow Up after Anti-VEGF Treatment

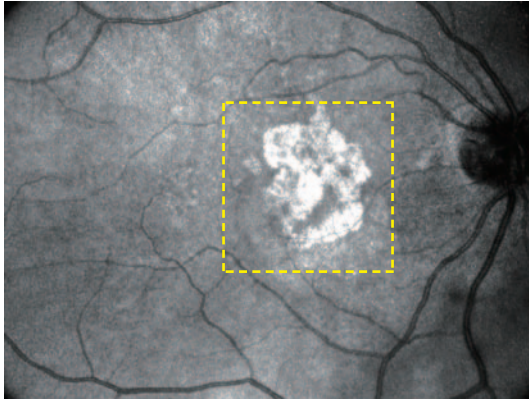


Fig. 1a: SLO

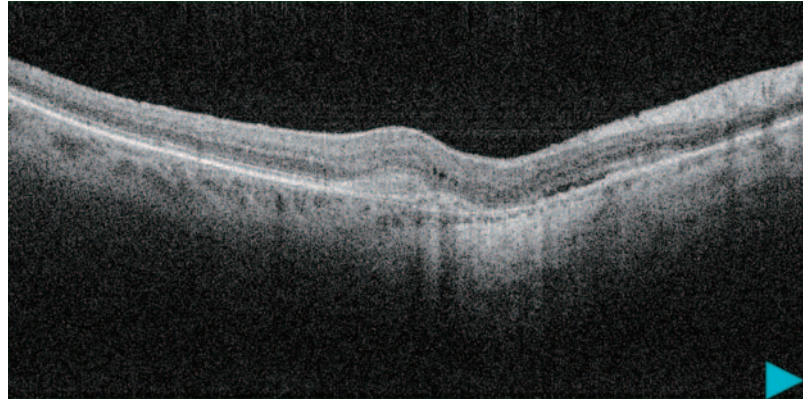
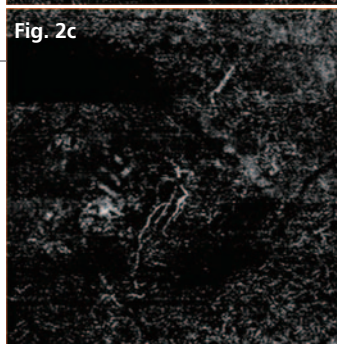
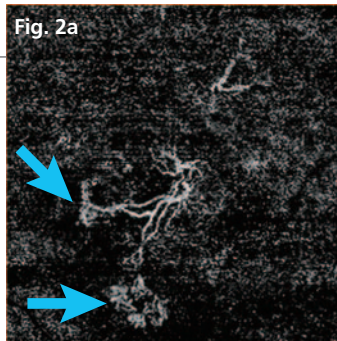


Fig. 1b: OCT B-scan

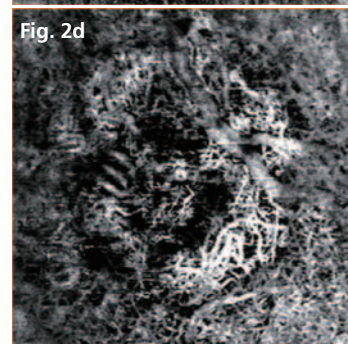
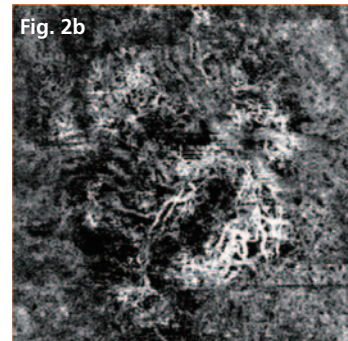
**Fig. 1a:** The SLO fundus image shows hyperreflective macular alterations corresponding to atrophic changes.

**Fig. 1b:** The structural OCT B-scan reveals rare intraretinal microcysts and subretinal fluid. Hyperreflective thickening below the retinal cysts is evident. Atrophic changes are also visible.

### PRE-TREATMENT



3.9 x 3.9 mm OCT-Angiography  
(Outer Retina)



3.9 x 3.9 mm OCT-Angiography  
(Choroid)

### POST-TREATMENT

#### ■ OCT-Angiography: AngioScan Images

**Fig. 2a/2b:** A neovascular membrane with a main trunk and numerous finely anastomosed peripheral branches are present in the outer retina. Atrophic changes are visible in the choroid.

**Fig. 2c/2d:** The vascular network decreased significantly after intravitreal anti-VEGF treatment. The main trunk seems to be reduced while the smaller and peripheral branches (blue arrows) disappeared completely.

# Case 6

## Atrophic Age-related Macular Degeneration (AMD)

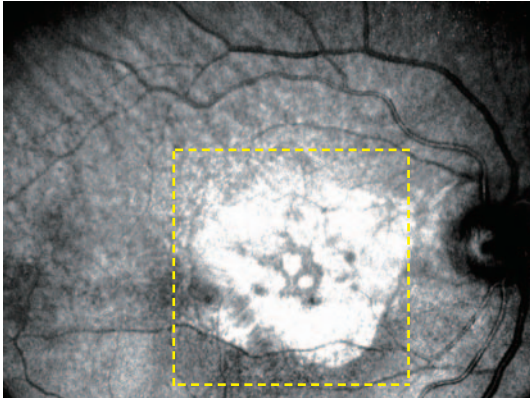


Fig. 1a: SLO

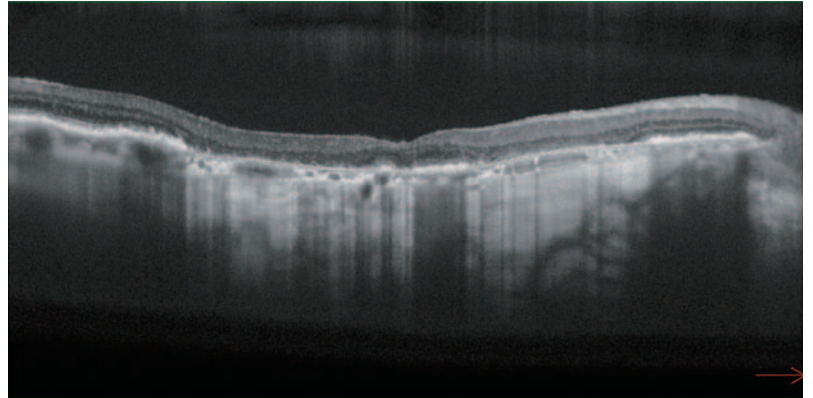


Fig. 1b: OCT B-scan

**Fig. 1a:** The SLO fundus image shows the Geographic Atrophy (GA) as a well demarcated wide hyperreflective area, with a circumscribed central foveal sparing.

**Fig. 1b:** The structural OCT B-scan shows macular thinning with RPE loss causing increased OCT signal intensity below Bruch's Membrane (Hyper-transmission).

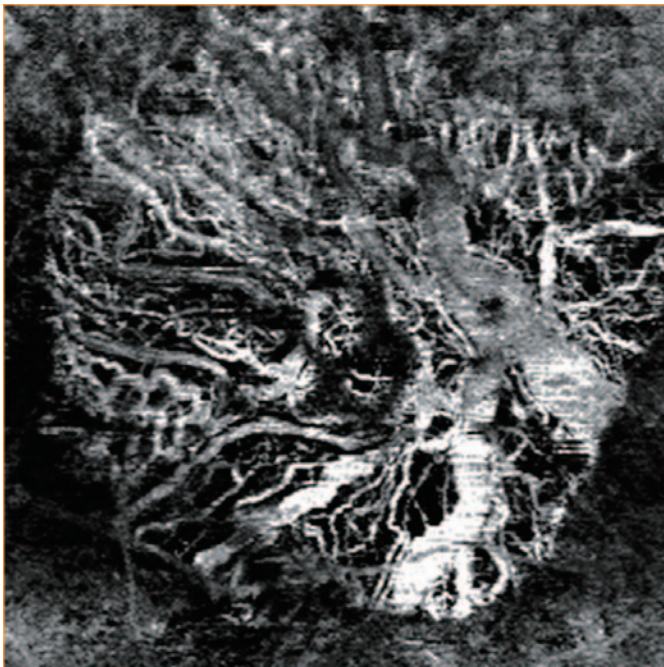


Fig. 2: 5.4 x 5.4 mm OCT-Angiography (Choroid)




Fig. 3: 5.4 x 5.4 mm En face (Choroid)

### ■ OCT-Angiography: AngioScan Images

**Fig. 2:** The 5.4 x 5.4 mm choroidal slab shows the increased visibility of the large choroidal vessels below the atrophic area with complete absence of choriocapillaris.

**Fig. 3:** The En face choroidal image outlines the shape of GA determined by the hyper-transmission through the atrophic RPE into the choroid.

# Case 7

## Myopic Choroidal Neovascularization (CNV)

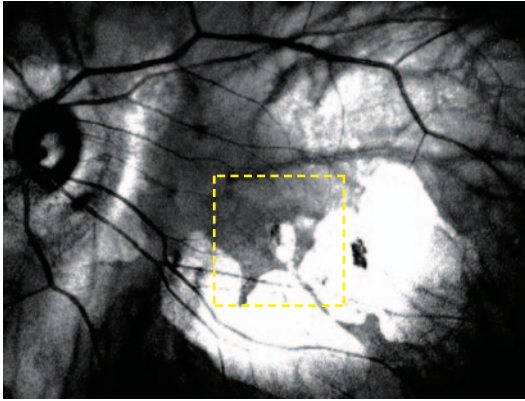


Fig. 1a: SLO

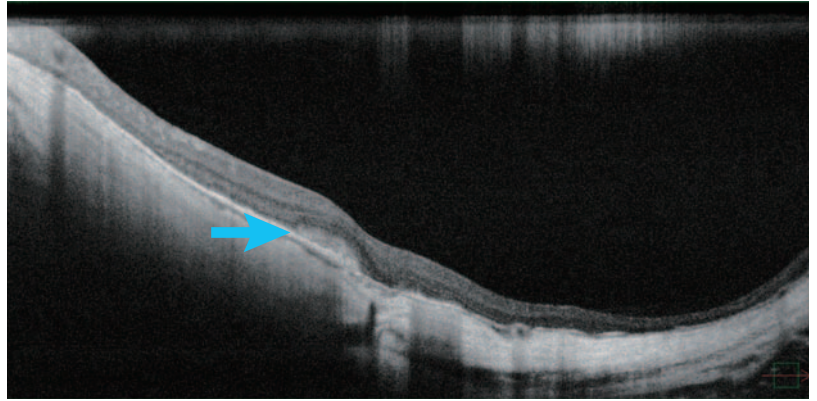
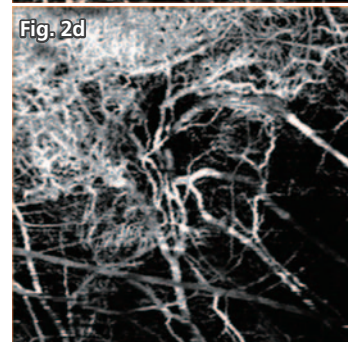
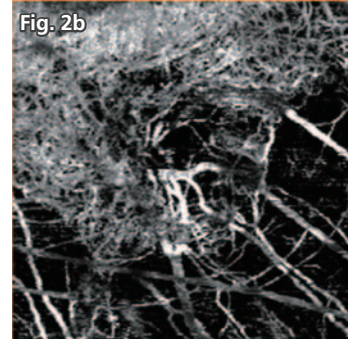
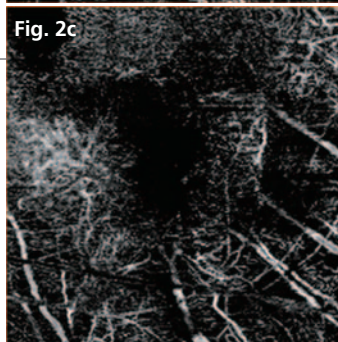
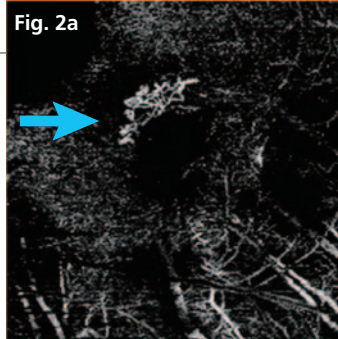


Fig. 1b: OCT B-scan

**Fig. 1a:** The SLO fundus image shows the typical tessellated appearance with the peripapillary and posterior atrophy due to pathological myopia.

**Fig. 1b:** The structural OCT B-scan shows a subfoveal hyperreflective lesion corresponding to the CNV (blue arrow).

### PRE-TREATMENT



OCT-Angiography (Outer Retina)

OCT-Angiography (Choroid)

### ■ OCT-Angiography: AngioScan Images

**Fig. 2a/2b:** The OCT-A confirms the presence of active myopic neovascular membrane present in the outer retina slab (Type II CNV).

**Fig. 2c/2d:** After anti-VEGF treatment, the vascular network in the outer retina completely disappeared. In this patient, new vessels cannot be clearly detected in the choroid, where atrophic changes predominate.

# Case 8

## Angioid Streaks associated with Choroidal Neovascularization (CNV)

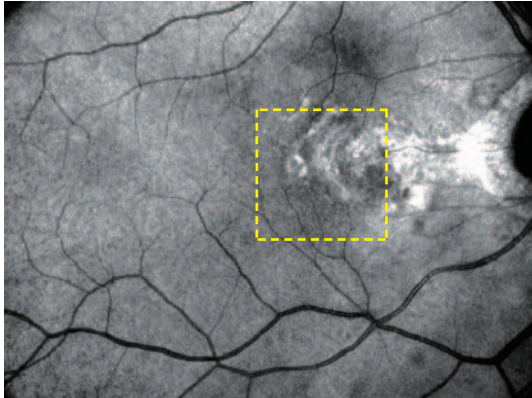


Fig. 1a: SLO

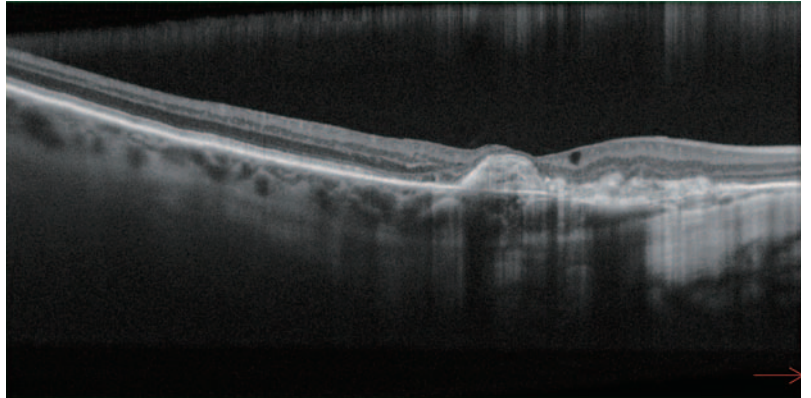


Fig. 1b: OCT B-scan

**Fig. 1a:** SLO fundus image of a fibrotic CNV complicating an eye with angioid streaks in a patient with pseudoxanthoma elasticum. Angioid streaks are not visible in this scan, whereas peau d'orange temporal to the posterior pole is well detected.

**Fig. 1b:** The structural OCT B-scan shows hyperreflective subretinal thickening without contiguous subretinal fluid (only a chronic intraretinal cyst is visible) corresponding to advanced fibrotic CNV.

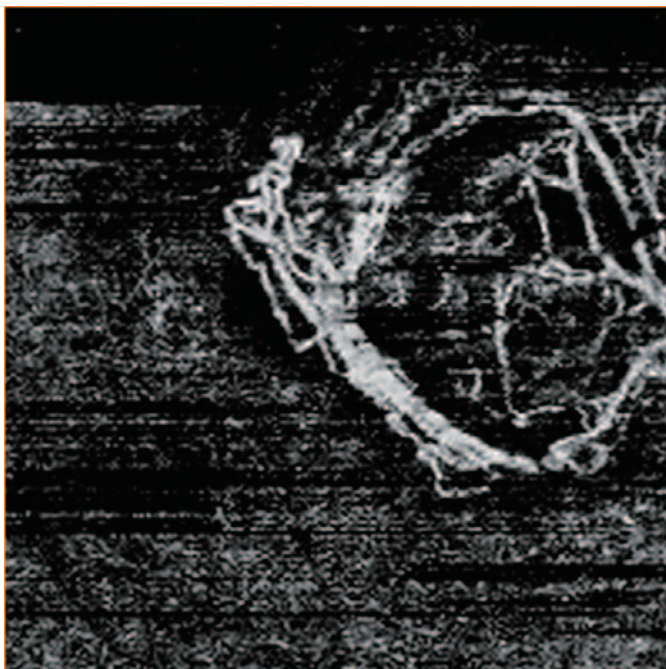


Fig. 2a: OCT-Angiography (Outer Retina)

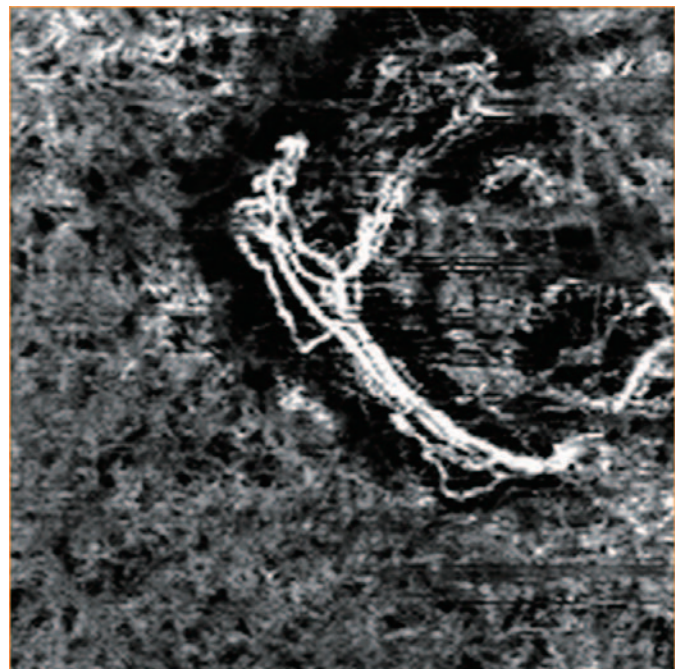


Fig. 2b: OCT-Angiography (Choroid)

### ■ OCT-Angiography: AngioScan Images

Abnormal neovascular networks are visible in the outer retina (Fig. 2a) and choroid (Fig. 2b). Large major arterialized trunks are associated with long filamentous and poorly anastomosed vessels. This pattern is typical of quiescent CNV.

# Case 9

## Advanced Stage Retinitis Pigmentosa (RP)

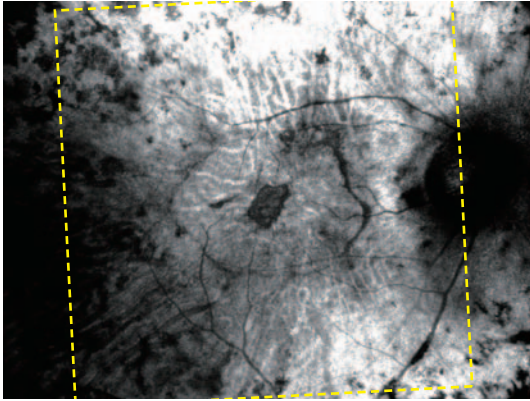


Fig. 1a: SLO

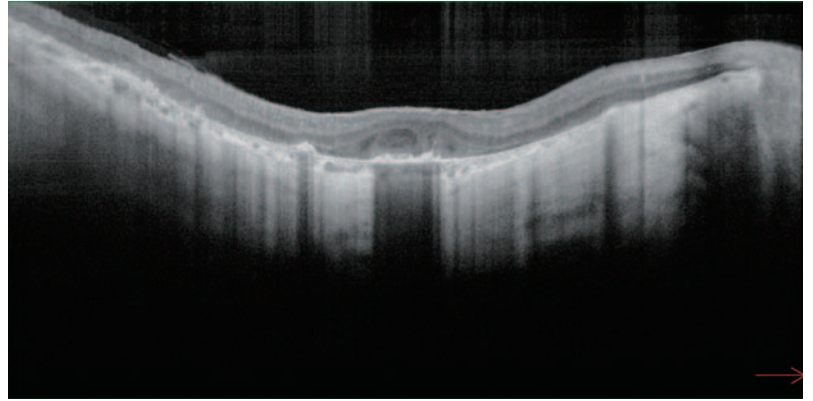


Fig. 1b: OCT B-scan

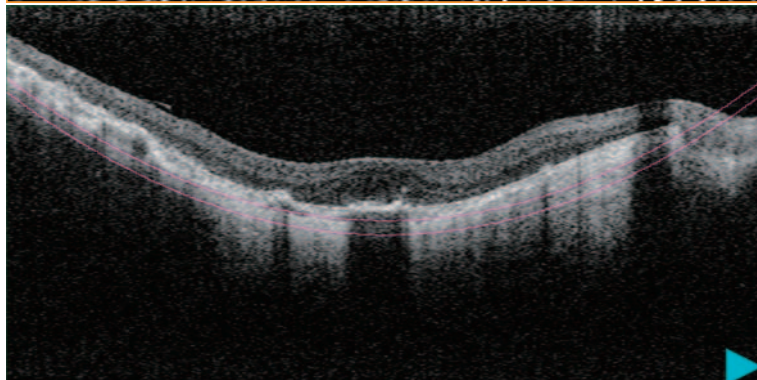
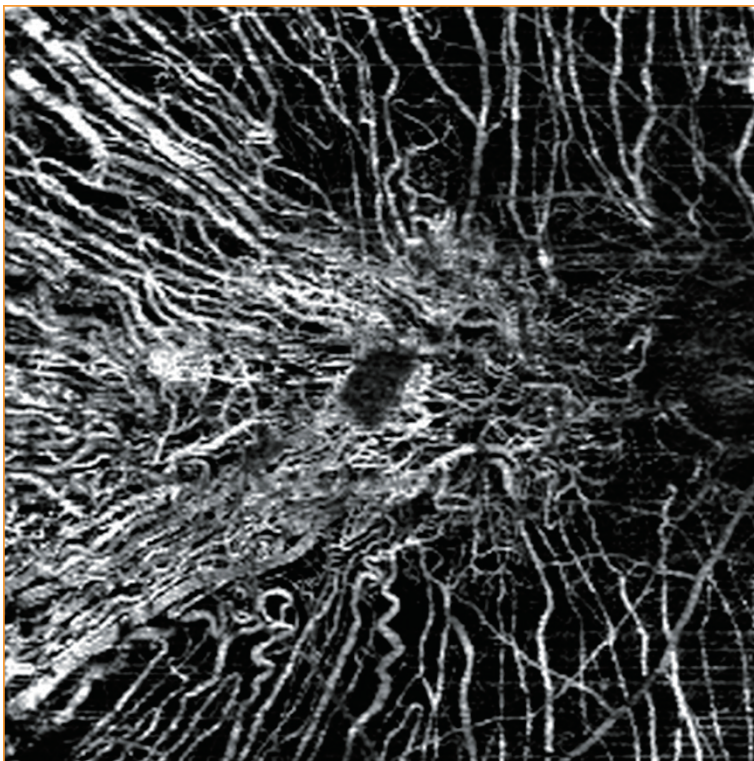


Fig. 2: 9 x 9 mm OCT-Angiography (Choroid)

**Fig. 1a:** SLO fundus picture of a 40 year-old patient with advanced stage RP. The patient carries a RHO mutation associated with a dominant inheritance pattern.

**Fig. 1b:** The structural OCT B-scan reveals complete absence of the ellipsoid zone except for a surviving central island.

### ■ OCT-Angiography: AngioScan Images

**Fig. 2:** The 9 x 9 mm choroidal slab shows the large choroidal vessels due to extensive loss of RPE and choriocapillaris.

# Case 10

## Stargardt (STGD) Disease

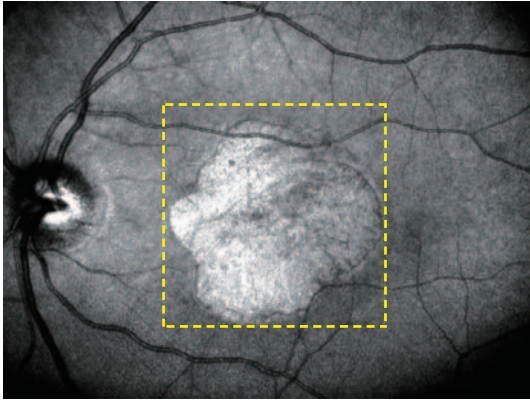


Fig. 1a: SLO

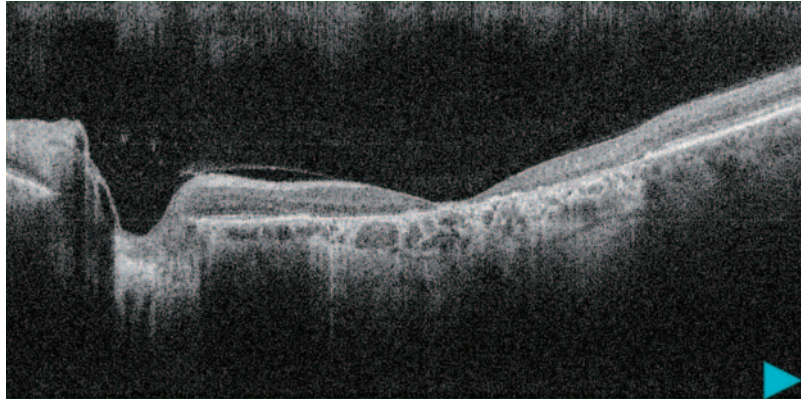


Fig. 1b: OCT B-scan

**Fig. 1a:** SLO fundus of a large hyperreflective area of macular atrophy in a patient affected by STGD disease carrying the pathogenic ABCA4 mutations.

**Fig. 1b:** The structural OCT B-scan image of decreased foveal thickness due to macular atrophy.

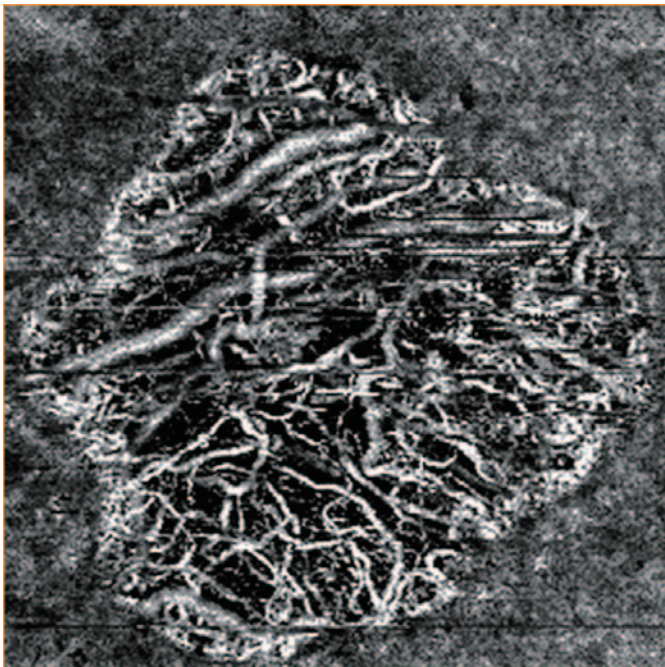

Fig. 2: 5.1 x 5.1 mm OCT-Angiography (Choroid)




Fig. 3: 5.1 x 5.1 mm En face (Choroid)

### ■ OCT-Angiography: AngioScan Images

**Fig. 2:** The 5.1 x 5.1 mm choroidal slab shows an optimal visualization of the large choroidal vessels and the borders of the atrophy from the extensive loss of the RPE and choriocapillaris layers.

**Fig. 3:** The extension of the atrophic area is confirmed by the related En face image.

# Case 11

## X-Linked Retinoschisis

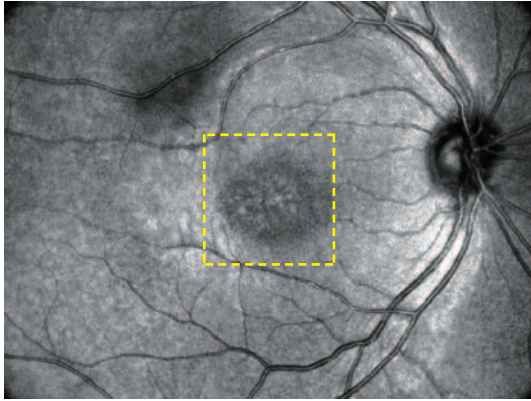


Fig. 1a: SLO

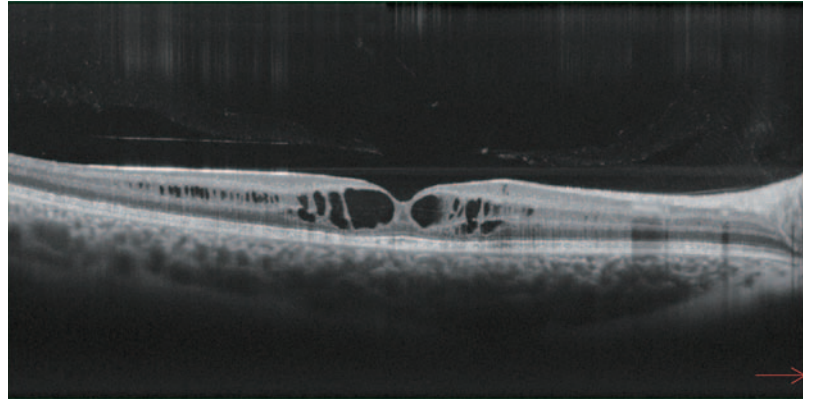


Fig. 1b: OCT B-scan

**Fig. 1a:** SLO fundus image of a 13 year-old male with X-Linked Retinoschisis and carrying the pathogenic XLR51 mutations. The image shows radiating hypo and hyperreflective areas.

**Fig. 1b:** The structural OCT B-scan shows splitting through multiple layers of the retina with foveal cysts.

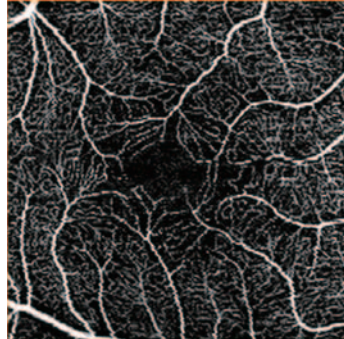


Fig. 2a: OCT-Angiography (SCP)

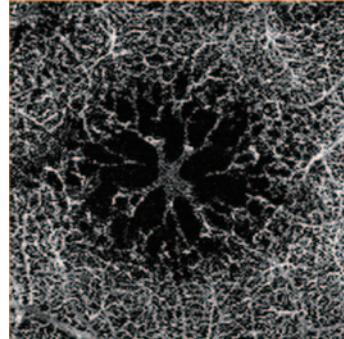


Fig. 2b: OCT-Angiography (DCP)

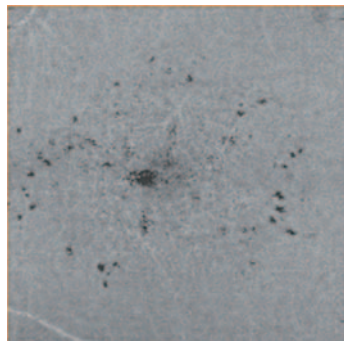


Fig. 3a: En face OCT (SCP)

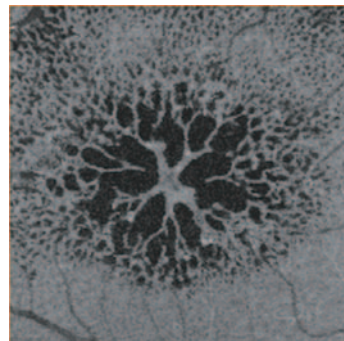


Fig. 3b: En face OCT (DCP)

### ■ OCT-Angiography: AngioScan Images

**Fig. 2a:** The superficial capillary plexus (SCP) seems normal.

**Fig. 2b:** Cystoid spaces are present in the deep capillary plexus (DCP). The image corresponds well to the En face OCT image (**Fig. 3b**). The borders of the cystoid spaces show a clearly detectable flow signal which suggests good vascularization in these structures.

# Case 12

## Choroidal Osteoma complicated by Choroidal Neovascularization (CNV)

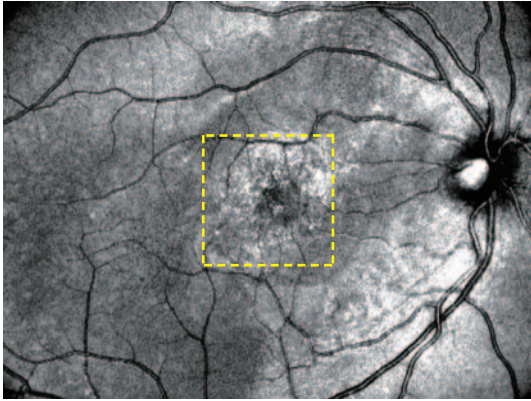


Fig. 1a: SLO

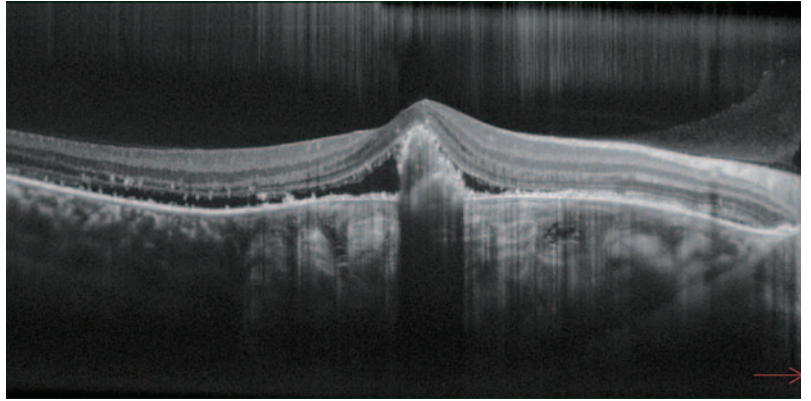


Fig. 1b: OCT B-scan

**Fig. 1a:** SLO fundus image of a young male patient with Choroidal Osteoma with a roundish highly reflective central area.

**Fig. 1b:** The structural OCT B-scan shows a sponge-like hyperreflectivity in the choroid associated with subretinal fluid and highly reflective speckles on the posterior surface of the detached neurosensory retina. A hyperreflective area above Bruch's Membrane with disruption of the outer retina is detectable.

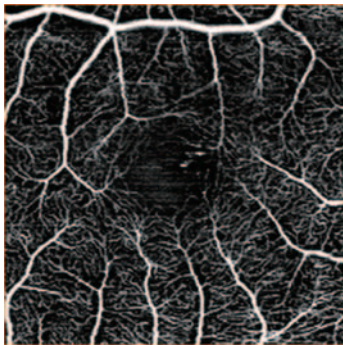


Fig. 2a: OCT-Angiography (SCP)




Fig. 2b: OCT-Angiography (DCP)

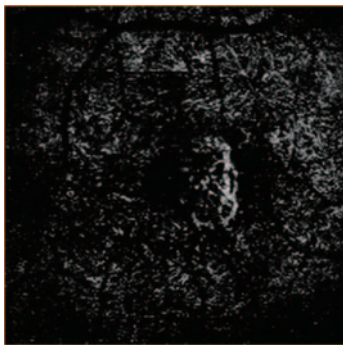


Fig. 2c: OCT-Angiography (Outer Retina)

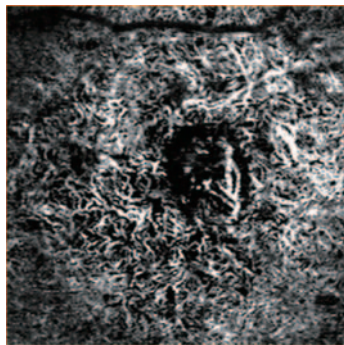


Fig. 2d: OCT-Angiography (Choroid)

### ■ OCT-Angiography: AngioScan Images

**Fig. 2a:** There are no relevant alterations in the superficial capillary plexus (SCP).

**Fig. 2b:** The foveal avascular zone (FAZ) is enlarged in the deep capillary plexus (DCP).

**Fig. 2c:** An abnormal flow signal in the outer retina indicates the presence of the CNV complicating the osteoma.

**Fig. 2d:** The choroidal slab shows a homogenous tumoral vascular network and the choroidal component of the CNV.

# Case 13

## Branch Retinal Vein Occlusion (BRVO)

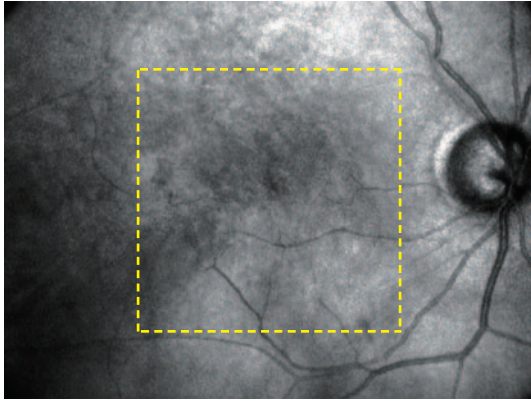


Fig. 1a: SLO

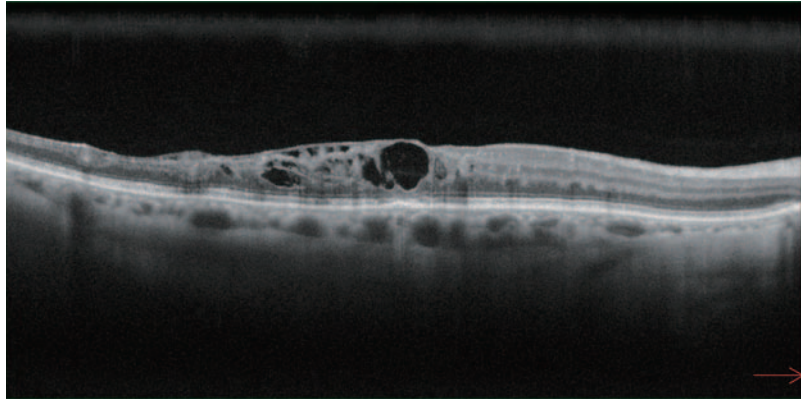


Fig. 1b: OCT B-scan

**Fig. 1a:** The SLO fundus image reveals microvascular abnormalities at the posterior pole.

**Fig. 1b:** The structural OCT B-scan of a patient with a longstanding superotemporal branch retinal vein occlusion showing cystoid macular edema.

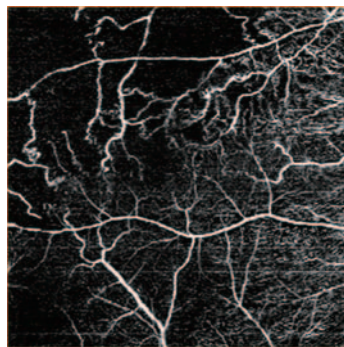


Fig. 2b: 6 x 6 mm OCT-Angiography (SCP)

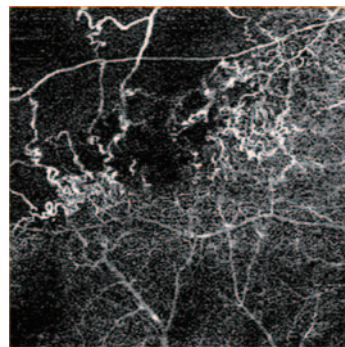


Fig. 2b: 6 x 6 mm OCT-Angiography (DCP)

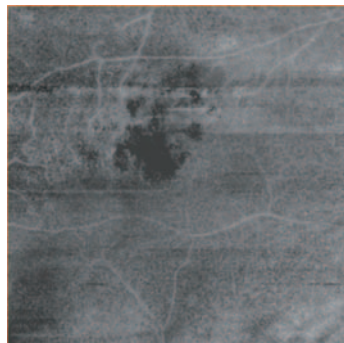


Fig. 3b: 6 x 6 mm En face OCT (SCP)

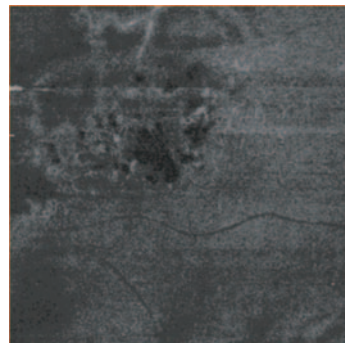


Fig. 3b: 6 x 6 mm En face OCT (DCP)

### ■ OCT-Angiography: AngioScan Images

**Fig. 2a/2b:** OCT-A highlights the well-demarcated regions of absent flow both at the superficial and deeper vascular plexus levels. Note the initial formation of anastomosis with the deep vascular network and collateral circulation.

**Fig. 3a/3b:** The respective En face OCT images of the superficial and deep plexus.

# Case 14

## Proliferative Diabetic Retinopathy (DR)

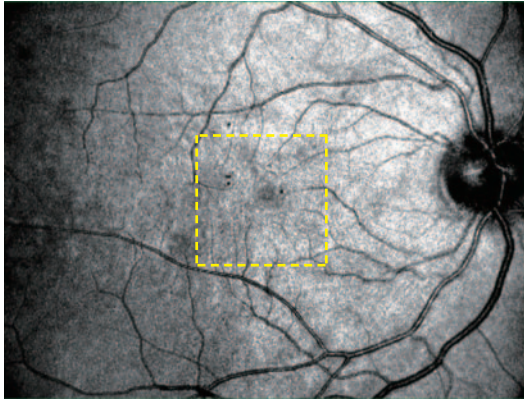


Fig. 1a: SLO (macula)

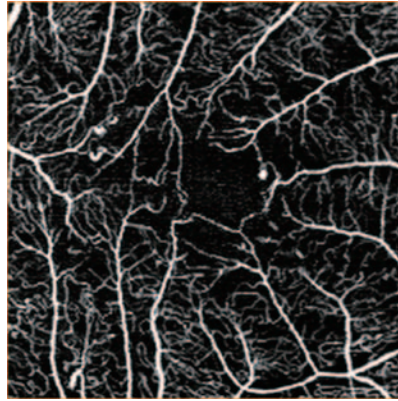


Fig. 2a: OCT-Angiography (SCP)

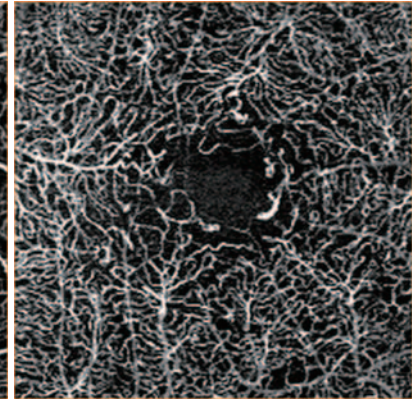


Fig. 2b: OCT-Angiography (DCP)

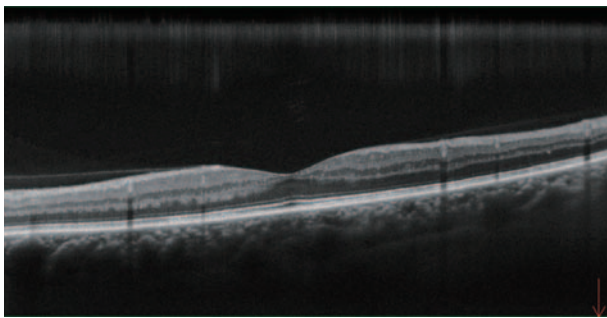


Fig. 1b: OCT B-scan (macula)

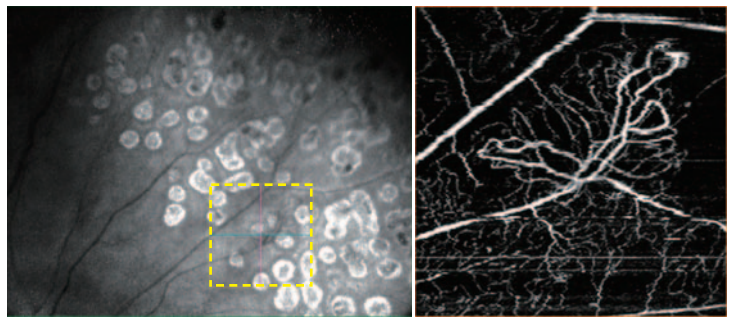


Fig. 3: Peripheral SLO & OCT-Angiography

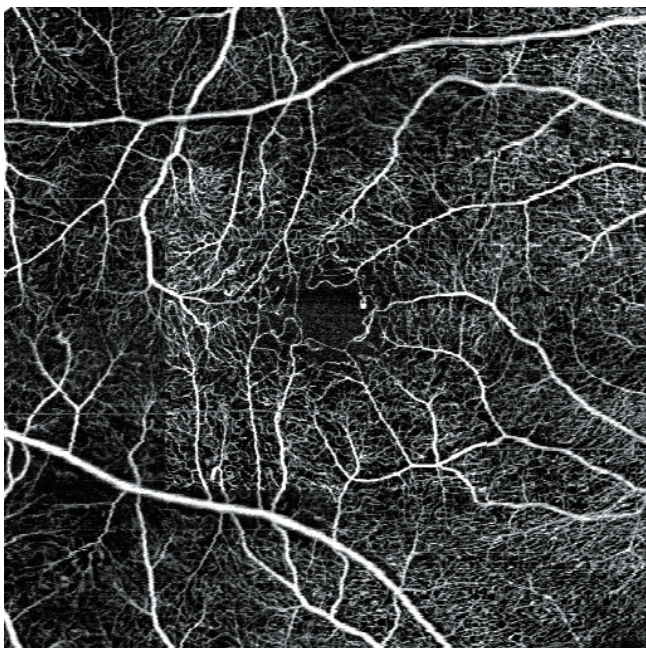


Fig. 4: 9 x 9 mm panoramic OCT-Angiography

**Fig. 1a:** The SLO image shows rare hyporeflective lesions corresponding to retinal microaneurysms and small retinal hemorrhages.

**Fig. 1b:** The structural OCT B-scan shows no relevant morphologic alteration of the macular region.

### ■ OCT-Angiography: AngioScan Images

OCT-A of the SCP (**Fig. 2a**) reveals significant widening of the foveal avascular zone (FAZ) and dilatation of the juxtafoveal vessels. A texture rarefaction is present. OCT-A of the DCP (**Fig. 2b**) shows microaneurysms and vascular congestion.

In **Fig. 3**, peripheral SLO fundus image shows laser photocoagulation spots in the peripheral retina. Peripheral OCT-A shows preretinal neovascularization, surrounded by areas of non-perfusion.

In **Fig. 4**, a 9 x 9 mm panoramic image is reconstructed. The foveal avascular zone is irregular and widened with areas of disruption of the capillary network. Dilatations characteristic of microaneurysms are detectable with extramacular texture rarefaction.



Eye & Health Care

**NIDEK CO., LTD.**

**HEAD OFFICE  
(International Div.)**

34-14 Maehama, Hiroishi  
Gamagori, Aichi 443-0038,  
JAPAN

TEL: +81-533-67-8895

URL: <http://www.nidek.com>

[Manufacturer]

**TOKYO OFFICE  
(International Div.)**

3F Sumitomo Fudosan Hongo  
Bldg., 3-22-5 Hongo, Bunkyo-ku,  
Tokyo 113-0033, JAPAN

TEL: +81-3-5844-2641

URL: <http://www.nidek.com>

**NIDEK INC.**

47651 Westinghouse Drive,  
Fremont, CA 94539, U.S.A.

TEL: +1-510-226-5700

+1-800-223-9044

(US only)

URL: <http://usa.nidek.com>

**NIDEK S.A.**

Europarc,  
13 rue Auguste Perret,  
94042 Créteil, FRANCE

TEL: +33-1-49 80 97 97

URL: <http://www.nidek.fr>

**NIDEK TECHNOLOGIES S.R.L.**

Via dell'Artigianato,  
6/A, 35020 Albignasego (Padova),  
ITALY

TEL: +39 049 8629200/8626399

URL: <http://www.nidektechnologies.it>

**NIDEK (SHANGHAI) CO., LTD.**

Rm3205, Shanghai Multi  
Media Park, No.1027 Chang  
Ning Rd, Chang Ning District,  
Shanghai, CHINA 200050,

TEL: +86 021-5212-7942

URL: <http://www.nidek-china.cn>

**NIDEK SINGAPORE PTE. LTD.**

51 Changi Business Park  
Central 2, #06-14, The  
Signature 486066,  
SINGAPORE

TEL: +65 6588 0389